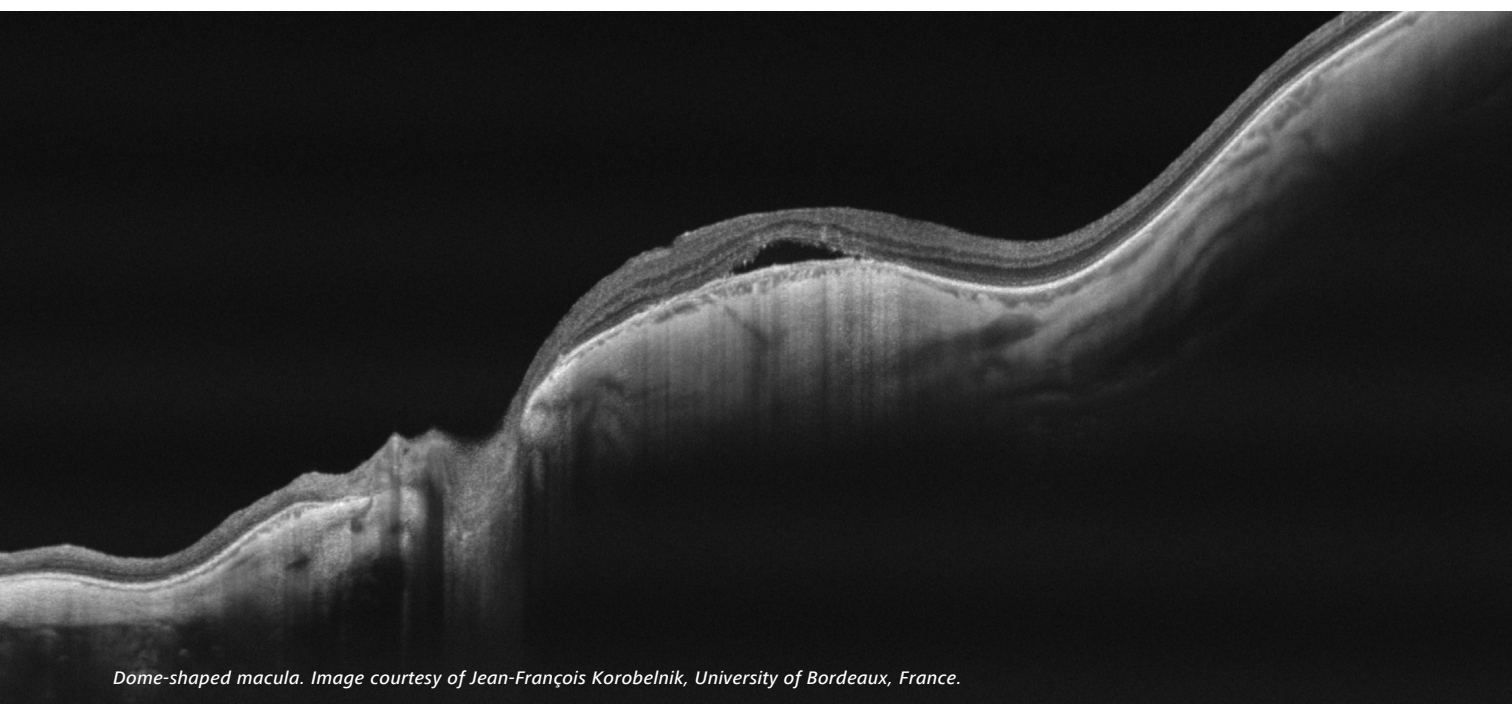


ZEISS PLEX Elite 9000

Swept-Source OCT & OCT Angiography



Dome-shaped macula. Image courtesy of Jean-François Korobelnik, University of Bordeaux, France.

Clinical compendium of peer-reviewed journal articles



Contents

Vascular Occlusions	3
Age-Related Macular Degeneration (AMD)	4
Diabetic Retinopathy	7
Retinoschisis	9
Central Serous Chorioretinopathy	9
Macular Telangiectasia	9
Tumors	10
Inflammation	10
Other Retina and Choroid	11
Glaucoma and Optic Neuropathies	13
Quantification	14
Health Subjects	15
Swept-Source OCT–OCTA Technology	16

Vascular Occlusions

1. Costanzo, E, Parravano, M, Gilardi, M, Cavalleri, M, Sacconi, R, Aragona, E, Varano, M, Bandello, F, Querques, G. **Microvascular Retinal and Choroidal Changes in Retinal Vein Occlusion Analyzed by Two Different Optical Coherence Tomography Angiography Devices.** *Ophthalmologica.* 2019;1
<https://www.ncbi.nlm.nih.gov/pubmed/30721901>
2. Tsai, G, Banaee, T, Conti, FF, Singh, RP. **Optical Coherence Tomography Angiography in Eyes with Retinal Vein Occlusion.** *J Ophthalmic Vis Res.* 2018;13(3):315 <https://www.ncbi.nlm.nih.gov/pubmed/30090189>
3. Motulsky, E, Zheng, F, Liu, G, Gregori, G, Rosenfeld, PJ. **Swept-Source OCT Angiographic Imaging of a Central Retinal Vein Occlusion During Pregnancy.** *Ophthalmic Surg Lasers Imaging Retina.* 2018;49(3):206
<https://www.ncbi.nlm.nih.gov/pubmed/29554389>
4. Freund, KB, Sarraf, D, Leong, BCS, Garrity, ST, Vupparaboina, KK, Dansingani, KK. **Association of Optical Coherence Tomography Angiography of Collaterals in Retinal Vein Occlusion with Major Venous Outflow through the Deep Vascular Complex.** *JAMA Ophthalmol.* 2018;136(11):1262 <https://www.ncbi.nlm.nih.gov/pubmed/30352115>
5. Arrigo, A, Carnevali, A, Sacconi, R, Querques, L, Querques, G, Bandello, F. **Spontaneous Retinal-Choroidal Anastomosis in a Case of Branch Retinal Vein Occlusion.** *Am J Ophthalmol Case Rep.* 2018;11:92 <https://www.ncbi.nlm.nih.gov/pubmed/30003175>
6. Zhang, Q, Chen, C-L, Chu, Z, Wang, RK. **Wide Field OCT Angiography by Using Swept-Source OCT in Living Human Eye.** *Ophthalmic Technologies XXVII.* 2017;10045:100450V https://spie.org/Publications/Proceedings/Paper/10.1117/12.2251029?origin_id=x4318
<https://www.spiedigitallibrary.org/conference-proceedings-of-spie/10045/1/Wide-field-OCT-angiography-by-using-swept-source-OCT-in/10.1117/12.2251029.short?SSO=1>
7. Jones, BP, Chen, MH, Jung, JJ, Hoang, QV, Inoue, M, Bala, C, Freud, KB, Yannuzzi, LA, Rofagha, S, Lee, A. **Comparison of OCT Angiography and Conventional Fluorescein Angiography in the Evaluation of Collateralization in Acute Versus Chronic Branch or Hemi Retinal Vein Occlusion.** *Invest Ophthalmol Vis Sci.* 2016 Sep;57(12):5473
<https://iovs.arvojournals.org/article.aspx?articleid=2563567&resultClick=1>
8. Lee, SY, Matsunaga, D, Yi, J, Durbin, MK, Puliafito, C, Kashani, AH. **Swept-Source OCT Angiography (OCTA) of Subjects with Retinal Vein Occlusions.** *Invest Ophthalmol Vis Sci.* 2015 Jun;56(7):3345 <https://iovs.arvojournals.org/article.aspx?articleid=2333203&resultClick=1>
9. Kuehlewein, L, An, L, Durbin, MK, Sadda, SR. **Imaging Areas of Retinal Nonperfusion in Ischemic Branch Retinal Vein Occlusion with Swept-Source OCT Microangiography.** *Ophthalmic Surg Lasers Imaging Retina.* 2015;46(2):249
<https://www.ncbi.nlm.nih.gov/pubmed/25707052>
<https://www.healio.com/ophthalmology/journals/osli/2015-2-46-2/{d4c82e7e-1918-45bc-8c9c-6478166f3393}/imaging-areas-of-retinal-nonperfusion-in-ischemic-branch-retinal-vein-occlusion-with-swept-source-oct-microangiography>
10. Kashani, AH, Lee, SY, Moshfeghi, A, Durbin, MK, Puliafito, CA. **Optical Coherence Tomography Angiography of Retinal Venous Occlusion.** *Retina.* 2015;35(11):2323 <https://www.ncbi.nlm.nih.gov/pubmed/26457395>
<https://insights.ovid.com/pubmed?pmid=26457395>

Age-Related Macular Degeneration (AMD)

1. von der Emde, L, Pfau, M, Thiele, S, Moller, PT, Hassenrik, R, Fleckenstein, M, Holz, FG, Schmitz-Valckenberg, S. **Mesopic and Dark-Adapted Two-Color Fundus-Controlled Perimetry in Choroidal Neovascularization Secondary to Age-Related Macular Degeneration.** *Transl Vis Sci Technol.* 2019;8(1):7 <https://www.ncbi.nlm.nih.gov/pubmed/30637177>
2. Cicinelli, MV, Cavalleri, M, Consorte, AC, Rabiolo, A, Sacconi, R, Bandello, F, Querques, G. **Swept-Source and Spectral Domain Optical Coherence Tomography Angiography Versus Dye Angiography in the Measurement of Type 1 Neovascularization.** *Retina.* 2019 <https://www.ncbi.nlm.nih.gov/pubmed/30649078>
3. Zheng, F, Motulsky, EH, de Oliveira Dias, JR, de Lopez, EP, Gregori, G, Rosenfeld, PJ. **OCT Angiography Helps Distinguish between Proliferative Macular Telangiectasia Type 2 and Neovascular Age-Related Macular Degeneration.** *Ophthalmic Surg Lasers Imaging Retina.* 2018;49(5):303 <https://www.ncbi.nlm.nih.gov/pubmed/29772040>
4. Zhang, Q, Zheng, F, Motulsky, EH, Gregori, G, Chu, Z, Chen, CL, Li, C, de Sistiernes, L, Durbin, M, Rosenfeld, PJ, Wang, RK. **A Novel Strategy for Quantifying Choriocapillaris Flow Voids Using Swept-Source OCT Angiography.** *Invest Ophthalmol Vis Sci.* 2018 Jan 1;59(1):203-11 <https://www.ncbi.nlm.nih.gov/pubmed/29340648>
5. Qin, J, Rinella, N, Zhang, Q, Zhou, H, Wong, J, Deiner, M, Roorda, A, Porco, TC, Wang, RK, Schwartz, DM, Duncan, JL. **OCT Angiography and Cone Photoreceptor Imaging in Geographic Atrophy.** *Invest Ophthalmol Vis Sci.* 2018 Dec 3;59(15):5985-92 <https://www.ncbi.nlm.nih.gov/pubmed/30572343>
6. Ohayon, A, Sacconi, R, Semoun, O, Corbelli, E, Souied, EH, Querques, G. **Choroidal Neovascular Area and Vessel Density Comparison between Two Swept-Source Optical Coherence Tomography Angiography Devices.** *Retina.* 2018 <https://www.ncbi.nlm.nih.gov/pubmed/30589664>
7. Namavari, A, Zheng, F, Motulsky, EH, de Oliveira Dias, JR, Gregori, G, Rosenfeld, PJ. **Swept-Source OCT Angiography Identifies Choroidal Neovascularization Arising from a Choroidal Nevus.** *Ophthalmic Surg Lasers Imaging Retina.* 2018;49(5):360 <https://www.ncbi.nlm.nih.gov/pubmed/29772047>
8. Muller, PL, Pfau, M, Moller, PT, Nadal, J, Schmid, M, Lindner, M, de Sistiernes, L, Stohr, H, Weber, BHF, Neuhaus, C, Herrmann, P, Schmitz-Valckenberg, S, Holz, FG, Fleckenstein, M. **Choroidal Flow Signal in Late-Onset Stargardt Disease and Age-Related Macular Degeneration: An OCT-Angiography Study.** *Invest Ophthalmol Vis Sci.* 2018 Mar 20;59(4):AMD122-31 <https://www.ncbi.nlm.nih.gov/pubmed/30140905>
9. Motulsky, EH, Zheng, F, Shi, Y, Gregori, G, Rosenfeld, PJ. **Anatomic Localization of Type 1 and Type 2 Macular Neovascularization Using Swept-Source OCT Angiography.** *Ophthalmic Surg Lasers Imaging Retina.* 2018;49(11):878 <https://www.ncbi.nlm.nih.gov/pubmed/30457647>
10. Marchese, A, Arrigo, A, Sacconi, R, Querques, L, Prascina, F, Pierro, L, Bandello, F, Querques, G. **Spectrum of Choroidal Neovascularisation Associated with Dome-Shaped Macula.** *Br J Ophthalmol.* 2018 <https://www.ncbi.nlm.nih.gov/pubmed/30327318>
11. de Oliveira Dias, JR, Zhang, Q, Garcia, JMB, Zheng, F, Motulsky, EH, Roisman, L, Miller, A, Chen, CL, Kubach, S, de Sistiernes, L, Durbin, MK, Feuer, W, Wang, RK, Gregori, G, Rosenfeld, PJ. **Natural History of Subclinical Neovascularization in Nonexudative Age-Related Macular Degeneration Using Swept-Source OCT Angiography.** *Ophthalmology.* 2018;125(2):255 <https://www.ncbi.nlm.nih.gov/pubmed/28964581>
12. Dansingani, KK, Gal-Or, O, Sadda, SR, Yannuzzi, LA, Freund, KB. **Understanding Aneurysmal Type 1 Neovascularization (Polypoidal Choroidal Vasculopathy): A Lesson in the Taxonomy of 'Expanded Spectra' - a Review.** *Clin Exp Ophthalmol.* 2018;46(2):189 <https://www.ncbi.nlm.nih.gov/pubmed/29178419>

13. Carnevali, A, Sacconi, R, Querques, L, Corbelli, E, Rabiolo, A, Chiara, G, Scorcia, V, Bandello, F, Querques, G. **Abnormal Quiescent Neovascularization in a Patient with Large Colloid Drusen Visualized by Optical Coherence Tomography Angiography.** *Retin Cases Brief Rep.* 2018;12 Suppl 1:S41 <https://www.ncbi.nlm.nih.gov/pubmed/29064855>
14. Borrelli, E, Shi, Y, Uji, A, Balasubramanian, S, Nassisi, M, Sarraf, D, Sadda, SR. **Topographic Analysis of the Choriocapillaris in Intermediate Age-Related Macular Degeneration.** *Am J Ophthalmol.* 2018;196:34 <https://www.ncbi.nlm.nih.gov/pubmed/30118688>
15. Sacconi R, SD, Garrity S, Freund KB, Yannuzzi LA, Gal-Or O, Souied E, Sieiro A, Corbelli E, Carnevali A, Querques L. **Abstracts.** *Ophthalmology.* 2018;125(12):1834
16. Zheng, F, Zhang, Q, Motulsky, EH, de Oliveira Dias, JR, Chen, CL, Chu, Z, Miller, AR, Feuer, W, Gregori, G, Kubach, S, Durbin, MK, Wang, RK, Rosenfeld, PJ. **Comparison of Neovascular Lesion Area Measurements from Different Swept-Source OCT Angiographic Scan Patterns in Age-Related Macular Degeneration.** *Invest Ophthalmol Vis Sci.* 2017 Oct 1;58(12):5098-104 <https://www.ncbi.nlm.nih.gov/pubmed/28986595>
<https://www.ncbi.nlm.nih.gov/pmc/articles/PMC5634352/pdf/i1552-5783-58-12-5098.pdf>
17. Zheng, F, Zhang, Q, Miller, AR, Dias, JR, Motulsky, EH, Liu, G, Chu, Z, Chen, C-L, Kubach, S, De Sisternes, L, Feuer, W, Gregori, G, Durbin, MK, Wang, RK, Rosenfeld, PJ. **Comparing Area Measurements of Choroidal Neovascularization Obtained Using Different Swept-Source OCT Angiographic Scan Patterns in Neovascular Age-Related Macular Degeneration.** *Invest Ophthalmol Vis Sci.* 2017 Jun;58(8):50 <https://iovs.arvojournals.org/article.aspx?articleid=2637946&resultClick=1>
18. Zhang, Q, Zhang, A, Lee, CS, Lee, AY, Rezaei, KA, Roisman, L, Miller, A, Zheng, F, Gregori, G, Durbin, MK, An, L, Stetson, PF, Rosenfeld, PJ, Wang, RK. **Projection Artifact Removal Improves Visualization and Quantitation of Macular Neovascularization Imaged by Optical Coherence Tomography Angiography.** *Ophthalmol Retina.* 2017;1(2):124 <https://www.ncbi.nlm.nih.gov/pubmed/28584883>
19. Zhang, Q, Chen, C-L, Chu, Z, Zheng, F, Miller, A, Roisman, L, de Oliveira Dias, JR, Yehoshua, Z, Schaal, KB, Feuer, W. **Automated Quantitation of Choroidal Neovascularization: A Comparison Study between Spectral-Domain and Swept-Source OCT Angiograms automated CNV Quantitation Using OCTA.** *Invest Ophthalmol Vis Sci.* 2017 Mar;58(3):1506-13 <https://iovs.arvojournals.org/article.aspx?articleid=2610163>
20. Stein, G, Zheng, F, Tran, AQ, Dias, JR, Motulsky, EH, Gregori, G, Rosenfeld, PJ. **Swept-Source OCT Angiography of Polypoidal Choroidal Vasculopathy Using Boundary Layer Specific Segmentation.** *Invest Ophthalmol Vis Sci.* 2017 Jun;58(8):1698 <https://iovs.arvojournals.org/article.aspx?articleid=2637816&resultClick=1>
21. Rabiolo, A, Sacconi, R, Cicinelli, MV, Querques, L, Bandello, F, Querques, G. **Spotlight on Reticular Pseudodrusen.** *Clin Ophthalmol.* 2017;11:1707 <https://www.ncbi.nlm.nih.gov/pubmed/29033536>
<https://www.dovepress.com/getfile.php?fileID=38507>
22. Motulsky, EH, Stein, G, Zhang, Q, Chen, C-L, Zheng, F, Liu, G, Dias, JR, Feuer, W, Wang, RK, Gregori, G, Rosenfeld, PJ. **Correlations between the Volumes of Fibrovascular Retinal Pigment Epithelial Detachments and the Areas of Type 1 Choroidal Neovascularization in Age-Related Macular Degeneration Using OCT Imaging.** *Invest Ophthalmol Vis Sci.* 2017 Jun;58(8):369 <https://iovs.arvojournals.org/article.aspx?articleid=2637133&resultClick=1>
23. Miller, AR, Roisman, L, Zhang, Q, Zheng, F, Rafael de Oliveira Dias, J, Yehoshua, Z, Schaal, KB, Feuer, W, Gregori, G, Chu, Z, Chen, CL, Kubach, S, An, L, Stetson, PF, Durbin, MK, Wang, RK, Rosenfeld, PJ. **Comparison between Spectral-Domain and Swept-Source Optical Coherence Tomography Angiographic Imaging of Choroidal Neovascularization.** *Invest Ophthalmol Vis Sci.* 2017 Mar 1;58(3):1499-1505 <https://www.ncbi.nlm.nih.gov/pubmed/28273316>
<https://www.ncbi.nlm.nih.gov/pmc/articles/PMC5361583/pdf/i1552-5783-58-3-1499.pdf>

24. Kubach, S, Lewis, W, Gregori, G, Rosenfeld, PJ. **Retinal Pigment Epithelium Layer Segmentation Accuracy on Widefield High-resolution Optical Coherence Tomography Cubes.** *Invest Ophthalmol Vis Sci.* 2017 Jun;58(8):661 <https://iovs.arvojournals.org/article.aspx?articleid=2637966&resultClick=1>
25. Dias, JR, Zhang, Q, Roisman, L, Zheng, F, Chen, C-L, Miller, AR, Motulsky, EH, Liu, G, Kubach, S, De Sisternes, L, Feuer, WJ, Gregori, G, Durbin, MK, Wang, RK, Rosenfeld, PJ. **Prevalence of Quiescent Neovascularization in Intermediate and Late Non-Exudative Age-Related Macular Degeneration and the Incidence of Subsequent Exudation Using Swept-Source Optical Coherence Tomography Angiography.** *Invest Ophthalmol Vis Sci.* 2017;58(8):55 <https://iovs.arvojournals.org/article.aspx?articleid=2637170&resultClick=1>
26. De Sisternes, L, Bagherinia, H, Kubach, S, Knighton, RW, Zheng, F, Gregori, G, Rosenfeld, PJ, Durbin, M. **Automated Case-Adaptive Slab Configuration for Visualization of Choroidal Neovascularization in Swept-Source OCT Angiography.** *Invest Ophthalmol Vis Sci.* 2017 Jun;58(8):372 <https://iovs.arvojournals.org/article.aspx?articleid=2637935&resultClick=1>
27. de Oliveira Dias, JR, Zhang, Q, Garcia, JMB, Zheng, F, Motulsky, EH, Roisman, L, Miller, A, Chen, CL, Kubach, S, de Sisternes, L, Durbin, MK, Feuer, W, Wang, RK, Gregori, G, Rosenfeld, PJ. **Natural History of Subclinical Neovascularization in Nonexudative Age-Related Macular Degeneration Using Swept-Source OCT Angiography.** *Ophthalmology.* 2017 <https://www.ncbi.nlm.nih.gov/pubmed/28964581>
28. Zheng, F, Roisman, L, Schaal, KB, Miller, AR, Robbins, G, Gregori, G, Rosenfeld, PJ. **Artifactual Flow Signals within Drusen Detected by OCT Angiography.** *Ophthalmic Surg Lasers Imaging Retina.* 2016;47(6):517 <https://www.ncbi.nlm.nih.gov/pubmed/27327280>
29. Zheng, F, Gregori, G, Schaal, KB, Legarreta, AD, Miller, AR, Roisman, L, Feuer, WJ, Rosenfeld, PJ. **Choroidal Thickness and Choroidal Vessel Density in Nonexudative Age-Related Macular Degeneration Using Swept-Source Optical Coherence Tomography Imaging.** *Invest Ophthalmol Vis Sci.* 2016;57(14):6256-6256 <https://www.ncbi.nlm.nih.gov/pubmed/27849311>
<https://www.ncbi.nlm.nih.gov/pmc/articles/PMC5114036/pdf/i1552-5783-57-14-6256.pdf>
30. Zhang, Q, A., Z, Lee, CS, Lee, A, Roisman, L, Gregori, G, Durbin, M, An, L, Stetson, PF, Rosenfeld, PJ, Wang, RK. **OCT-Based Angiography of Choroidal Neovascularization by Removing Projection Artifacts*.** *Invest Ophthalmol Vis Sci.* 2016 Sep;57(12) <https://iovs.arvojournals.org/article.aspx?articleid=2558422&resultClick=1>
31. Schaal, KB, Legarreta, AD, Feuer, W, Gregori, G, Cheng, Q, Legarreta, J, Stetson, PF, Kubach, S, Rosenfeld, PJ. **Masked Assessment of Widefield En Face Swept-Source OCT Imaging Versus Color, Autofluorescence, and Infrared Fundus Imaging for the Diagnosis of Reticular Pseudodrusen*.** *Invest Ophthalmol Vis Sci.* 2016 Sep;57(12):1609 <https://iovs.arvojournals.org/article.aspx?articleid=2560239&resultClick=1>
32. Roisman, L, Qinqin, Z, Ruikang KW, Gregori, G, Zhang, A, Chen, CL, et al. **Swept-Source Optical Coherence Tomography Angiography of Asymptomatic Neovascularization in Intermediate Age-Related Macular Degeneration.** *Invest Ophthalmol Vis Sci.* 2016 Sep;57(12):4939 <https://iovs.arvojournals.org/article.aspx?articleid=2563112&resultClick=1>
33. Roisman, L, Zhang, Q, Wang, RK, Gregori, G, Zhang, A, Chen, C-L, Durbin, MK, An, L, Stetson, PF, Rosenfeld, PJ. **Optical Coherence Tomography Angiography of Indocyanine Green Angiographic Plaques in Asymptomatic Intermediate Age-Related Macular Degeneration*.** *Ophthalmology.* 2016 Jun;123(6):1309 <https://www.ncbi.nlm.nih.gov/pubmed/26876696>
<https://www.ncbi.nlm.nih.gov/pmc/articles/PMC5120960/pdf/nihms830277.pdf>
34. Roisman, L, Zhang, Q, Wang, RK, Gregori, G, Zhang, A, Chen, CL, Durbin, MK, An, L, Stetson, PF, Robbins, G, Miller, A, Zheng, F, Rosenfeld, PJ. **Optical Coherence Tomography Angiography of Asymptomatic Neovascularization in Intermediate Age-Related Macular Degeneration.** *Ophthalmology.* 2016 Jun;123(6):1309 <https://www.ncbi.nlm.nih.gov/pubmed/26876696>

<https://www.ncbi.nlm.nih.gov/pmc/articles/PMC5120960/pdf/nihms830277.pdf>

35. Miller, A, Zheng, F, Schaal, KB, Roisman, L, Legarreta, AD, Feuer, W, Rosenfeld, PJ, Gregori, G. **Widefield Swept-Source OCT Choroidal Thickness Maps and Choroidal Vessel Distribution in Eyes with Dry Age-Related Macular Degeneration***. *Invest Ophthalmol Vis Sci*. 2016 Sep;57(12):4942 <https://iovs.arvojournals.org/article.aspx?articleid=2563115&resultClick=1>
36. Jung, JJ, Chen, MH, Chung, PY, Lee, SS. **Swept-Source Optical Coherence Tomography Angiography for Choroidal Neovascularization after Bevacizumab and Photodynamic Therapy***. *Amer J Ophthalmol Case Reports*. 2016;1:1 <http://www.sciencedirect.com/science/article/pii/S245199361530013X>
37. Schaal, KB, Legarreta, AD, Gregori, G, Legarreta, JE, Cheng, Q, Stetson, PF, Cai, M, Laron, M, Durbin, M, Rosenfeld, PJ. **Widefield En Face Optical Coherence Tomography Imaging of Subretinal Drusenoid Deposits**. *Ophthalmic Surg Lasers Imaging Retina*. 2015;46(5):550 <https://www.ncbi.nlm.nih.gov/pubmed/26057758>
<https://www.healio.com/ophthalmology/journals/osli/2015-5-46-5/{ab88275a-55a9-4562-be3d-203ec772e063}/widefield-en-face-optical-coherence-tomography-imaging-of-subretinal-drusenoid-deposits>
38. Shi, Y, Motulsky, E, Goldhart R, et al. **Predictive Value of the OCT Double-Layer Sign for Identifying Subclinical Neovascularization in Age-Related Macular Degeneration**. *Ophthalmol Retina*. 2019 Mar;3(3):211-19. [https://www.ophthalmologyretina.org/article/S2468-6530\(18\)30495-0/fulltext](https://www.ophthalmologyretina.org/article/S2468-6530(18)30495-0/fulltext)
39. Thulliez, M, Motulsky, E, Feuer, W, et al. **En Face Imaging of Geographic Atrophy Using Different Swept-Source OCT Scan Patterns**. *Ophthalmol Retina*. 2019 Feb;3(2):122-32. [https://www.ophthalmologyretina.org/article/S2468-6530\(18\)30378-6/fulltext](https://www.ophthalmologyretina.org/article/S2468-6530(18)30378-6/fulltext)
40. Lek, JJ, Caruso, E, Baglin EK, et al. **Interpretation of Subretinal Fluid Using OCT in Intermediate Age-Related Macular Degeneration**. *Ophthalmol Retina*. 2018 Aug;2(8):792-802. [https://www.ophthalmologyretina.org/article/S2468-6530\(17\)30731-5/fulltext](https://www.ophthalmologyretina.org/article/S2468-6530(17)30731-5/fulltext)
41. Thulliez, M, Zang, Q, Shi, Y, et al. **Correlations between Choriocapillaris Flow Deficits around Geographic Atrophy and Enlargement Rates Based on Swept-Source OCT Imaging**. *Ophthalmol Retina*. doi: 10.1016/oret.2019.01.024 [Epub ahead of print] [https://www.ophthalmologyretina.org/article/S2468-6530\(18\)30617-1/fulltext](https://www.ophthalmologyretina.org/article/S2468-6530(18)30617-1/fulltext)

Diabetic Retinopathy

1. Breazzano, MP, Fernández-Avellaneda, P, Freund, KB. **Swept-Source Optical Coherence Tomography Angiography of Retinal Arterial Macroaneurysm With Overlying Hemorrhage**. *JAMA Ophthalmol*. 2019 Apr 1;137(4):e190247 <https://www.ncbi.nlm.nih.gov/pubmed/30973588>
2. Schaal, KB, Munk, MR, Wyssmueller, I, Berger, LE, Zinkernagel, MS, Wolf, S. **Vascular Abnormalities in Diabetic Retinopathy Assessed with Swept-Source Optical Coherence Tomography Angiography Widefield Imaging**. *Retina*. 2019;39(1):79 <https://www.ncbi.nlm.nih.gov/pubmed/29135803>
3. Hirano, T, Kitahara, J, Toriyama, Y, Kasamatsu, H, Murata, T, Sadda, S. **Quantifying Vascular Density and Morphology Using Different Swept-Source Optical Coherence Tomography Angiographic Scan Patterns in Diabetic Retinopathy**. *Br J Ophthalmol*. 2019;103(2):216 <https://www.ncbi.nlm.nih.gov/pubmed/29706601>
4. Zhang, Q, Rezaei, KA, Saraf, SS, Chu, Z, Wang, F, Wang, RK. **Ultra-Wide Optical Coherence Tomography Angiography in Diabetic Retinopathy**. *Quant Imaging Med Surg*. 2018;8(8):743 <https://www.ncbi.nlm.nih.gov/pubmed/30306055>
5. Yasukura, S, Murakami, T, Suzuma, K, Yoshitake, T, Nakanishi, H, Fujimoto, M, Oishi, M, Tsujikawa, A. **Diabetic**

- Nonperfused Areas in Macular and Extramacular Regions on Wide-Field Optical Coherence Tomography Angiography.** *Invest Ophthalmol Vis Sci.* 2018;59(15):5893 <https://www.ncbi.nlm.nih.gov/pubmed/30550612>
6. Shroff, D, Gupta, P, Gupta, C, Shroff, C. **Post-Laser Regression of Diabetic Neovascularization: An Optical Coherence Tomography Angiography Study.** *Indian J Ophthalmol.* 2018;66(12):1855 <https://www.ncbi.nlm.nih.gov/pubmed/30451198>
 7. Sawada, O, Ichiyama, Y, Obata, S, Ito, Y, Kakinoki, M, Sawada, T, Saishin, Y, Ohji, M. **Comparison between Wide-Angle OCT Angiography and Ultra-Wide Field Fluorescein Angiography for Detecting Non-Perfusion Areas and Retinal Neovascularization in Eyes with Diabetic Retinopathy.** *Graefes Arch Clin Exp Ophthalmol.* 2018;256(7):1275 <https://www.ncbi.nlm.nih.gov/pubmed/29713816>
 8. Fenner, BJ, Wong, RLM, Lam, WC, Tan, GSW, Cheung, GCM. **Advances in Retinal Imaging and Applications in Diabetic Retinopathy Screening: A Review.** *Ophthalmol Ther.* 2018;7(2):333 <https://www.ncbi.nlm.nih.gov/pubmed/30415454>
 9. Zhang, Q, Chen, CL, Attaran-Rezaei, K, Wang, RK. **Ultra-Wide Field Optical Coherence Tomography Angiography for Evaluation of Diabetic Retinopathy.** *Invest Ophthalmol Vis Sci.* 2017 Jun;58(8):5447 <https://iovs.arvojournals.org/article.aspx?articleid=2638241&resultClick=1>
 10. Schaal, KB, Munk, MR, Wyssmueller, I, Berger, L, Zinkernagel, MS, Wolf, S. **Vascular Abnormalities in Diabetic Retinopathy Assessed with Swept-Source Optical Coherence Tomography Angiography Widefield Imaging.** *Retina,* 2019 Jan;39(1):79-87 <https://www.ncbi.nlm.nih.gov/pubmed/29135803>
 11. Sawada, O, Ichiyama, Y, Ito, Y, Kakinoki, M, Sawada, T, Saishin, Y, Ohji, M. **Comparison between Wide Angle OCT Angiography and Ultra-Wide Field Fluorescein Angiography on the Detection of Non-Perfusion Area.** *Invest Ophthalmol Vis Sci.* 2017 Jun;58(8):1700 <https://iovs.arvojournals.org/article.aspx?articleid=2639517&resultClick=1>
 12. Kwon, JY, Kashani, AH, Liu, G, Zheng, F, Miller, A, Chu, Z, Wang, RK, Gregori, G, Rosenfeld, PJ. **Suspended Scattering Particles in Motion (Sspim): A Feature of OCT Angiography in Diabetic Macular Edema.** *Invest Ophthalmol Vis Sci.* 2017 Jun;58(8):937 <https://iovs.arvojournals.org/article.aspx?articleid=2638014&resultClick=1>
 13. Korobelnik, JF, Rougier, MB, Delyfer, MN. **[Wide Field OCT-Angiography of a Patient with Proliferative Diabetic Retinopathy].** [Article in French] *J Fr Ophthalmol.* 2017;40(8):721 <https://www.ncbi.nlm.nih.gov/pubmed/28912061>
 14. Shahidzadeh, A, Kim, AY, Aziz, HA, Durbin, MK, Puliafito, C, Kashani, AH. **Widefield Swept-Source Optical Coherence Tomography Angiography*.** *Invest Ophthalmol Vis Sci.* 2016 Sep;57(12):445 <https://iovs.arvojournals.org/article.aspx?articleid=2558091&resultClick=1>
 15. Cheng, S, Leng, T. **Noninvasive Detection of Microaneurysms in Diabetic Retinopathy by Swept-Source Optical Coherence Tomography*.** *Clin Ophthalmol.* 2016;10:1791 <https://www.ncbi.nlm.nih.gov/pubmed/27695284>
 16. Matsunaga, D, Yi, J, Olmos, LC, Legarreta, J, Legarreta, AD, Gregori, G, Sharma, A, Rosenfeld, PJ, Puliafito, C, Kashani, AH. **OCT Angiography (OCTA) of Diabetic Retinopathy*.** *Invest Ophthalmol Vis Sci.* 2015 Jun;56(7):3335. <https://iovs.arvojournals.org/article.aspx?articleid=2333192&resultClick=1>
 17. Russell, JF, Shi, Y, Hinkle, J, et al. **Longitudinal Wide-Field Swept-Source OCT Angiography of Neovascularization in Proliferative Diabetic Retinopathy after Panretinal Photocoagulation.** *Ophthalmol Retina.* 2019 Apr;3(4):350-61. [https://www.opthalmologyretina.org/article/S2468-6530\(18\)30604-3/fulltext](https://www.opthalmologyretina.org/article/S2468-6530(18)30604-3/fulltext)

Retinoschisis

1. Fragiotta, S, Leong, BCS, Kaden, TR, Bass, SJ, Sherman, J, Yannuzzi, LA, Freund, KB. **A Proposed Mechanism Influencing Structural Patterns in X-Linked Retinoschisis and Stellate Nonhereditary Idiopathic Foveomacular Retinoschisis.** *Eye (Lond)*. 2018 Dec 5. doi: 10.1038/s41433-018-0296-8. [Epub ahead of print] <https://www.ncbi.nlm.nih.gov/pubmed/30518975>
2. Han, IC, Whitmore, SS, Critser BD, et al. **Wide-Field Swept-Source OCT and Angiography in X-Linked Retinoschisis.** *Ophthalmol Retina*. 2019 Feb;3(2): 178-85 [https://www.opthalmologyretina.org/article/S2468-6530\(18\)30424-X/fulltext](https://www.opthalmologyretina.org/article/S2468-6530(18)30424-X/fulltext)

Central Serous Chorioretinopathy

1. Zucchiatti, I, Sacconi, R, Parravano, MC, Costanzo, E, Querques, L, Montorio, D, Bandello, F, Querques, G. **Eplerenone Versus Observation in the Treatment of Acute Central Serous Chorioretinopathy: A Retrospective Controlled Study.** *Ophthalmol Ther*. 2018 Jun;7(1):109 <https://www.ncbi.nlm.nih.gov/pubmed/29442283>
2. Ogawa, Y, Maruko, I, Koizumi, H, Iida, T. **Quantification of Choroidal Vasculature by High-Quality Structure En Face Swept-Source Optical Coherence Tomography Images in Eyes with Central Serous Chorioretinopathy.** *Retina*. 2018 Dec [Epub ahead of print] <https://www.ncbi.nlm.nih.gov/pubmed/30550530>

Macular Telangiectasia

1. Robbins, G, Roisman, L, Zhang, Q, Wang, RK, Gregori, G, Chen, CL, Durbin, M, Stetson, PF, Legarreta, AD, Miller, A, Rosenfeld, PJ. **OCT Angiography (OCTA) of Neovascularization in Macular Telangiectasia Type 2.** *Invest Ophthalmol Vis Sci*. 2016 Sep;57(12):5502 <https://iovs.arvojournals.org/article.aspx?articleid=2563579&resultClick=1>
2. Zhang, Q, Wang, RK, Chen, CL, Legarreta, AD, Durbin, MK, An, L, Sharma, U, Stetson, PF, Legarreta, JE, Roisman, L, Gregori, G, Rosenfeld, PJ. **Swept-Source Optical Coherence Tomography Angiography of Neovascular Macular Telangiectasia Type 2.** *Retina*. 2015;35(11):2285 <https://www.ncbi.nlm.nih.gov/pubmed/26457402>
<https://www.ncbi.nlm.nih.gov/pmc/articles/PMC4623930/pdf/nihms-721576.pdf>
3. Thorell, MR, Zhang, Q, Huang, Y, An, L, Durbin, MK, Laron, M, Sharma, U, Stetson, PF, Gregori, G, Wang, RK, Rosenfeld, PJ. **Swept-Source OCT Angiography of Macular Telangiectasia Type 2.** *Ophthalmic Surg Lasers Imaging Retina*. 2014;45(5):369 <https://www.ncbi.nlm.nih.gov/pubmed/25291783>
<https://www.healio.com/ophthalmology/journals/osli/2014-9-45-5/{849feaaa-8a02-4232-92ec-8b4fd894db7d}/swept-source-oct-angiography-of-macular-telangiectasia-type-2>

Tumors

1. Pellegrini, M, Corvi, F, Invernizzi, A, Ravera, V, Cereda, MG, Staurengi, G. **Swept-Source Optical Coherence Tomography Angiography in Choroidal Melanoma: An Analysis of 22 Consecutive Cases.** *Retina*. 2018 May. [Epub ahead of print] <https://www.ncbi.nlm.nih.gov/pubmed/29863536>
2. Ito, Y, Ohji, M. **Long-Term Follow-up of Congenital Simple Hamartoma of the Retinal Pigment Epithelium: A Case Report.** *Case Rep Ophthalmol*. 2018;9(1):215 <https://www.ncbi.nlm.nih.gov/pubmed/29681839>
3. Pellegrini, M, Staurengi, G. **Swept-Source Optical Coherence Tomography Angiography Imaging in a Case of Uveal Melanoma.** *Ophthalmology*. 2017 May;124(5):729 <https://www.ncbi.nlm.nih.gov/pubmed/28433129>
4. Pellegrini, M, Corvi, F, Ravera, V, Staurengi, G. **Swept-Source Optical Coherence Tomography Angiography in Choroidal Melanoma.** *Invest Ophthalmol Vis Sci*. 2017 Jun;58(8):1694 <https://iovs.arvojournals.org/article.aspx?articleid=2637815&resultClick=1>

Inflammation

1. Wintergerst, MWM, Pfau, M, Muller, PL, Berger, M, de Sisternes, L, Holz, FG, Finger, RP. **Optical Coherence Tomography Angiography in Intermediate Uveitis.** *Am J Ophthalmol*. 2018 Oct;194:35 <https://www.ncbi.nlm.nih.gov/pubmed/30026083>
2. Swaminathan, SS, Zheng, F, Miller, AR, Gregori, G, Davis, JL, Rosenfeld, PJ. **Swept-Source OCT Angiography of Multiple Evanescent White Dot Syndrome with Inflammatory Retinal Pigment Epithelial Detachment.** *Ophthalmic Surg Lasers Imaging Retina*. 2018 Feb;49(2):145 <https://www.ncbi.nlm.nih.gov/pubmed/29443367>
3. Rodriguez, M, Gregori, NZ, Roisman, L, Lam, BL, Rosenfeld, PJ. **Swept-Source OCT Imaging of the Argus II Epiretinal Prosthesis.** *Ophthalmol Retina*. 2018 Apr;2(4):380-82 [https://www.opthalmologyretina.org/article/S2468-6530\(17\)30458-X/fulltext](https://www.opthalmologyretina.org/article/S2468-6530(17)30458-X/fulltext)
4. Pakzad-Vaezi, K, Khaksari, K, Chu, Z, Van Gelder, RN, Wang, RK, Pepple, KL. **Swept-Source OCT Angiography of Serpiginous Choroiditis.** *Ophthalmol Retina*. 2018 Jul;2(7):712 <https://www.ncbi.nlm.nih.gov/pubmed/30148243>
5. Zahid, S, Chen, KC, Jung, JJ, Balaratnasingam, C, Ghadiali, Q, Sorenson, J, Rofagha, S, Freund, KB, Yannuzzi, LA. **Optical Coherence Tomography Angiography of Chorioretinal Lesions Due to Idiopathic Multifocal Choroiditis.** *Retina*. 2017 Aug;37(8):1451-63 <https://www.ncbi.nlm.nih.gov/m/pubmed/27880741>
http://journals.lww.com/retinajournal/Citation/2017/08000/OPTICAL_COHERENCE_TOMOGRAPHY_ANGIOGRAPHY_OF.4.aspx
<https://insights.ovid.com/pubmed?pmid=27880741>
6. Montorio, D, Giuffre, C, Miserocchi, E, Modorati, G, Sacconi, R, Mercuri, S, Querques, L, Querques, G, Bandello, F. **Swept-Source Optical Coherence Tomography Angiography in Serpiginous Choroiditis.** *Br J Ophthalmol*. 2017 Jul;102(7):991-95 <https://www.ncbi.nlm.nih.gov/pubmed/28982952>
<http://bj.o.bmj.com/content/early/2017/10/05/bjophthalmol-2017-310989.long>
7. Khaksari, K, Pakzad-Vaezi, K, Pepple, KL, Wang, RK. **Optical Coherence Tomography Based-Microangiography of Macular Edema in Uveitis.** *Invest Ophthalmol Vis Sci*. 2017 Jun;58(8):526 <https://iovs.arvojournals.org/article.aspx?articleid=2638689&resultClick=1>

8. Jung, JJ, Chen, MH, Rofagha, S, Lee, SS. **Graft-Versus-Host Disease Panuveitis and Bilateral Serous Detachments: Multimodal Imaging Analysis.** *Retin Cases Brief Rep.* 2017;11 Suppl 1:S54 <https://www.ncbi.nlm.nih.gov/pubmed/27571426>
<https://insights.ovid.com/pubmed?pmid=27571426>
9. Finger, RP, Wintergerst, M, Holz, FG. **Swept-Source Optical Coherence Tomography Angiography Findings in Uveitis: Novel Biomarkers for Disease Activity?** *Invest Ophthalmol Vis Sci.* 2017 Jun;58(8):1885 <https://iovs.arvojournals.org/article.aspx?articleid=2639659&resultClick=1>
10. Chu, Z, Pepple, KL, Wang, RK. **Quantitative Analysis of Choriocapillaris in Uveitic and Normal Subjects with SS-OCT Angiography.** *Invest Ophthalmol Vis Sci.* 2017 Jun;58(8):1871 <https://iovs.arvojournals.org/article.aspx?articleid=2638333&resultClick=1>

Other Retina and Choroid

1. Pellegrini, M, Cozzi, M, Staurengi, G, Corvi, F. **Comparison of Wide Field Optical Coherence Tomography Angiography With Extended Field Imaging and Fluorescein Angiography in Retinal Vascular Disorders.** *PLoS One.* 2019 Apr <https://journals.plos.org/plosone/article?id=10.1371/journal.pone.0214892>
2. Leong, BC, Gal-Or, O, Freund, KB. **Optical Coherence Tomography Angiography of Retinal-Choroidal Anastomosis in Toxoplasmosis Chorioretinitis.** *JAMA ophthalmology.* 2019 Mar 1;137(3):e184091 <https://www.ncbi.nlm.nih.gov/pubmed/30869760>
3. Thulliez, M, Zhang, Q, Shi, Y, Zhou, H, Chu, Z, de Sistiernes, L, Durbin, MK, Feuer, W, Gregori, G, Wang, RK, Rosenfeld, PJ. **Correlations between Choriocapillaris Flow Deficits around Geographic Atrophy and Enlargement Rates Based on Swept-Source OCT Imaging.** *Ophthalmol Retina.* 2019 [In press] [https://www.ophtalmologyretina.org/article/S2468-6530\(18\)30617-1/fulltext](https://www.ophtalmologyretina.org/article/S2468-6530(18)30617-1/fulltext)
4. Rezkallah, A, Kodjikian, L, Abukhashabah, A, Denis, P, Mathis, T. **Hypertensive Choroidopathy: Multimodal Imaging and the Contribution of Wide-Field Swept-Source OCT-Angiography.** *Am J Ophthalmol Case Rep.* 2019 Jan9;13:131-35 <https://www.ncbi.nlm.nih.gov/pubmed/30705996>
5. Puyo, L, Paques, M, Fink, M, Sahel, J-A, Atlan, M. **Choroidal Vasculature Imaging with Laser Doppler Holography.** *Biomed Opt Express.* 2019 Feb1;10(2):995-1012 <https://www.ncbi.nlm.nih.gov/pmc/articles/PMC6377881/>
6. Motulsky, E, Zheng, F, Shi, Y, Garcia, JMB, Gregori, G, Rosenfeld, PJ. **Imaging of Epiretinal Membranes Using En Face Widefield Swept-Source Optical Coherence Tomography.** *Ophthalmic Surg Lasers Imaging Retina.* 2019 Feb 1;50(2):106-12 <https://www.ncbi.nlm.nih.gov/pubmed/30768218>
7. Tran, AQ, Yannuzzi, NA, Motulsky, EH, Zhou, XY, Galor, A, Dubovy, SR, Rosenfeld, PJ, Lam, BL. **Swept-Source Optical Coherence Tomography Angiography of an Amalric Choroidal Infarction in a Rare Presentation of Giant Cell Arteritis with Bilateral Corneal Edema.** *Ophthalmic Surg Lasers Imaging Retina.* 2018 Oct 1;49(10):e157-60 <https://www.ncbi.nlm.nih.gov/pubmed/30395679>
8. Swaminathan, SS, Shah, P, Zheng, F, Gregori, G, Rosenfeld, PJ. **Detection of Choriocapillaris Loss in Alport Syndrome with Swept-Source OCT Angiography.** *Ophthalmic Surg Lasers Imaging Retina.* 2018 Feb 1;49(2):138-41 <https://www.ncbi.nlm.nih.gov/pubmed/29443365>
9. Sakurada, Y, Leong, BCS, Parikh, R, Fragiotta, S, Freund, KB. **Association between Choroidal Caverns and Choroidal Vascular Hyperpermeability in Eyes with Pachychoroid Diseases.** *Retina.* 2018 Oct;38(10):1977-83 <https://www.ncbi.nlm.nih.gov/pubmed/30198969>

10. Rodriguez, M, Gregori, NZ, Roisman, L, Lam, BL, Rosenfeld, PJ. **Swept-Source OCT Imaging of the Argus II Epiretinal Prosthesis.** *Ophthalmol Retina.* 2018 Apr;2(4):380-82 [https://www.opthalmologyretina.org/article/S2468-6530\(17\)30458-X/fulltext](https://www.opthalmologyretina.org/article/S2468-6530(17)30458-X/fulltext)
11. Paavo, M, Zhao, J, Kim, HJ, Lee, W, Zernant, J, Cai, C, Allikmets, R, Tsang, SH, Sparrow, JR. **Mutations in GPR143/OA1 and ABCA4 Inform Interpretations of Short-Wavelength and Near-Infrared Fundus Autofluorescence.** *Invest Ophthalmol Vis Sci.* 2018 May;59(6):2459-69 <https://www.ncbi.nlm.nih.gov/pubmed/29847651>
12. Montorio, D, Giuffre, C, Miserocchi, E, Modorati, G, Sacconi, R, Mercuri, S, Querques, L, Querques, G, Bandello, F. **Swept-Source Optical Coherence Tomography Angiography in Serpiginous Choroiditis.** *Br J Ophthalmol.* 2018;102(7):991 <https://www.ncbi.nlm.nih.gov/pubmed/28982952>
13. Laueremann, JL, Eter, N, Alten, F. **Optical Coherence Tomography Angiography Offers New Insights into Choriocapillaris Perfusion.** *Ophthalmologica.* 2018;239(2-3):74 <https://www.ncbi.nlm.nih.gov/pubmed/29353272>
14. Kashani, AH, Green, KM, Kwon, J, Chu, Z, Zhang, Q, Wang, RK, Garrity, S, Sarraf, D, Rebhun, CB, Waheed, NK, Schaal, KB, Munk, MR, Gattoussi, S, Freund, KB, Zheng, F, Liu, G, Rosenfeld, PJ. **Suspended Scattering Particles in Motion: A Novel Feature of OCT Angiography in Exudative Maculopathies.** *Ophthalmol Retina.* 2018;2(7):694 <https://www.ncbi.nlm.nih.gov/pubmed/30221214>
15. Kashani, AH, Green, KM, Kwon, J, Chu, Z, Zhang, Q, Wang, RK, Garrity, S, Sarraf, D, Rebhun, CB, Waheed, NK, Schaal, KB, Munk, MR, Gattoussi, S, Freund, KB, Zheng, F, Liu, G, Rosenfeld, PJ. **Suspended Scattering Particles in Motion: A Novel Feature of OCT Angiography in Exudative Maculopathies.** *Ophthalmol Retina.* 2018;2(7):694 <https://www.ncbi.nlm.nih.gov/pubmed/30221214>
16. Iesato, Y, Tanaka, M, Murata, M, Kitahara, J, Hirano, T, Kurenuma, T, Yoshida, N, Murata, T. **Complete Regression of Branching Vascular Network in Polypoidal Choroidal Vasculopathy by Ranibizumab and Photodynamic Therapy, Two Case Reports.** *BMC Ophthalmol.* 2018 Nov 3;18(1):284 <https://www.ncbi.nlm.nih.gov/pubmed/30390650>
17. Hayashi, K, Sato, T, Manabe, S-i, Hirata, A. **Sex-Related Differences in the Progression of Posterior Vitreous Detachment with Age.** *Ophthalmol Retina.* 2019 Mar;3(3):237-43 [https://www.opthalmologyretina.org/article/S2468-6530\(18\)30499-8/fulltext](https://www.opthalmologyretina.org/article/S2468-6530(18)30499-8/fulltext)
18. Dolz-Marco, R, Glover, JP, Gal-Or, O, Litts, KM, Messinger, JD, Zhang, Y, Cozzi, M, Pellegrini, M, Freund, KB, Staurengi, G, Curcio, CA. **Choroidal and Sub-Retinal Pigment Epithelium Caverns: Multimodal Imaging and Correspondence with Friedman Lipid Globules.** *Ophthalmology.* 2018 Aug;125(8):1287-1301 <https://www.ncbi.nlm.nih.gov/pubmed/29625839>
19. Cornut, T, Seguy, C, Rougier, MB, Delyfer, MN, Morillon, C, Korobelnik, JF. **[Multimodal Imaging in Multiple Traumatic Choroidal Ruptures].** [Article in French]. *J Fr Ophtalmol.* 2018 Sep;41(7):676-78 <https://www.ncbi.nlm.nih.gov/pubmed/30166234>
20. Casalino, G, Arrigo, A, Romano, F, Munk, MR, Bandello, F, Parodi, MB. **Acute Macular Neuroretinopathy: Pathogenetic Insights from Optical Coherence Tomography Angiography.** *Br J Ophthalmol.* 2019 Mar;109(3):410-14 <https://www.ncbi.nlm.nih.gov/pubmed/29844084>
21. Carnevali, A, Sacconi, R, Corbelli, E, Querques, L, Bandello, F, Querques, G. **Choroidal Caverns: A Previously Unreported Optical Coherence Tomography Finding in Best Vitelliform Dystrophy.** *Ophthalmic Surg Lasers Imaging Retina.* 2018 Apr 1;49(4):284-87 <https://www.ncbi.nlm.nih.gov/pubmed/29664989>
22. Yannuzzi, NA, Swaminathan, SS, Zheng, F, Miller, A, Gregori, G, Davis, JL, Rosenfeld, PJ. **Swept-Source OCT Angiography Shows Sparing of the Choriocapillaris in Multiple Evanescent White Dot Syndrome.** *Ophthalmic Surg Lasers Imaging Retina.* 2017 Jan 1;48(1):69-74 <https://www.ncbi.nlm.nih.gov/pubmed/28060397>

23. Stein, G, Zheng, F, Tran, AQ, Dias, JR, Motulsky, EH, Gregori, G, Rosenfeld, PJ. **Swept-Source OCT Angiography of Polypoidal Choroidal Vasculopathy Using Boundary Layer Specific Segmentation.** *Invest Ophthalmol Vis Sci.* 2017 Jun;58(8):1698 <https://iovs.arvojournals.org/article.aspx?articleid=2637816&resultClick=1>
24. Schaal, KB, Legarreta, AD, Feuer, WJ, Gregori, G, Cheng, Q, Legarreta, JE, Durbin, MK, Stetson, PF, Kubach, S, Rosenfeld, PJ. **Comparison between Widefield En Face Swept-Source OCT and Conventional Multimodal Imaging for the Detection of Reticular Pseudodrusen.** *Ophthalmology.* 2017 Feb;124(2):205-14 <https://www.ncbi.nlm.nih.gov/pubmed/27856030>
25. Sacconi, R, Freund, KB, Yannuzzi, LA, Dolz-Marco, R, Souied, E, Capuano, V, Semoun, O, Phasukkijwatana, N, Sarraf, D, Carnevali, A, Querques, L, Bandello, F, Querques, G. **The Expanded Spectrum of Perifoveal Exudative Vascular Anomalous Complex.** *Am J Ophthalmol.* 2017 Dec;184:137-46 <https://www.ncbi.nlm.nih.gov/pubmed/29079450>
26. Marchese, A, Miserocchi, E, Modorati, G, Rabiolo, A, Poggiali, E, Lattanzio, R, De Vitis, L, Querques, L, Querques, G, Bandello, F. **Widefield OCT Angiography of Idiopathic Retinal Vasculitis, Aneurysms, and Neuroretinitis.** *Ophthalmol Retina.* 2017 Nov-Dec;1(6):567-69 [https://www.ophtalmologyretina.org/article/S2468-6530\(17\)30008-8/fulltext](https://www.ophtalmologyretina.org/article/S2468-6530(17)30008-8/fulltext)
27. Jung, JJ, Chen, MH, Frambach, CR, Rofagha, S, Lee, SS. **Spectral Domain Versus Swept-Source Optical Coherence Tomography Angiography of the Retinal Capillary Plexuses in Sickle Cell Maculopathy.** *Retin Cases Brief Rep.* 2016 Spring;12(2):87-92 <https://www.ncbi.nlm.nih.gov/pubmed/27749746>
<https://insights.ovid.com/pubmed?pmid=27749746>
28. Zhang, Q, Wang, RK, Chen, CL, Legarreta, AD, Durbin, MK, An, L, Sharma, U, Stetson, PF, Legarreta, JE, Roisman, L, Gregori, G, Rosenfeld, PJ. **Swept-Source Optical Coherence Tomography Angiography of Neovascular Macular Telangiectasia Type 2.** *Retina.* 2015 Nov;35(11):2285-99 <https://www.ncbi.nlm.nih.gov/pubmed/26457402>
<https://www.ncbi.nlm.nih.gov/pmc/articles/PMC4623930/pdf/nihms-721576.pdf>

Glaucoma and Optic Neuropathies

1. Sousa, DC, Sacconi, R, Bandello, F, Querques, G. **Scleral Cyst Associated with Anomalous Tilted Configuration of the Optic Nerve Head: A Case Report.** *Ophthalmol Ther.* 2019 Mar;8(1):149-53 <https://www.ncbi.nlm.nih.gov/pubmed/30739279>
2. Rougier, MB, Le Goff, M, Korobelnik, JF. **Optical Coherence Tomography Angiography at the Acute Phase of Optic Disc Edema.** *Eye Vis (Lond).* 2018 Jun;5:15 <https://www.ncbi.nlm.nih.gov/pubmed/29977949>
3. Triolo, G, Rabiolo, A, Shemonski, ND, Fard, A, Di Matteo, F, Sacconi, R, Bettin, P, Magazzeni, S, Querques, G, Vazquez, LE, Barboni, P, Bandello, F. **Optical Coherence Tomography Angiography Macular and Peripapillary Vessel Perfusion Density in Healthy Subjects, Glaucoma Suspects, and Glaucoma Patients.** *Invest Ophthalmol Vis Sci.* 2017 Nov;58(13):5713-22 <https://www.ncbi.nlm.nih.gov/pubmed/29114838>
<https://iovs.arvojournals.org/article.aspx?articleid=2661826>
4. Triolo, G, Rabiolo, A, Galasso, M, De Vitis, L, Sacconi, R, Di Matteo, F, Bettin, P, Barboni, P, Querques, G, Bandello, F, vazquez, LE. **Assessment of Peripapillary and Macular Vessel Density Estimated with OCT-Angiography in Glaucoma Suspects and Glaucoma Patients.** *Invest Ophthalmol Vis Sci.* 2017 Jun;58(8):715 <https://iovs.arvojournals.org/article.aspx?articleid=2638812&resultClick=1>
6. Srinivas, S, Dastiridou, A, Durbin, MK, Nittala, MG, Huang, AA, Tan, JC, Francis, BA, Sadda, SR, Chopra, V. **Pilot Study of Lamina Cribrosa Intensity Measurements in Glaucoma Using Swept-Source Optical Coherence Tomography.** *J Glaucoma.* 2017 Feb;26(2):138-43 <https://www.ncbi.nlm.nih.gov/pubmed/27977479>
<https://insights.ovid.com/pubmed?pmid=27977479>

7. Chen, C-L, Nobrega, P, Wen, JC, Mudumbai, R, Menda, S, Johnstone, M, Chen, PP, Wang, RK. **Microvasculature Changes in Macular Region in Glaucomatous Eyes Using Optical Coherence Tomography-Based Angiography (OCTA).** *Invest Ophthalmol Vis Sci.* 2017 Jun;58(8):1677 <https://iovs.arvojournals.org/article.aspx?articleid=2637414&resultClick=1>
8. Blaesj, JM, Shemonski, N, Straub, J. **Quantification of Retinal Blood Flow Using Doppler OCT with a PLEX™ Elite 9000.** *Invest Ophthalmol Vis Sci.* 2017 Jun;58(8):726 <https://iovs.arvojournals.org/article.aspx?articleid=2638574&resultClick=1>

Quantification

1. Zhang, Q, Zheng, F, Motulsky, EH, Gregori, G, Chu, Z, Chen, CL, Li, C, de Sisternes, L, Durbin, M, Rosenfeld, PJ, Wang, RK. **A Novel Strategy for Quantifying Choriocapillaris Flow Voids Using Swept-Source OCT Angiography.** *Invest Ophthalmol Vis Sci.* 2018 Jan 1;59(1):203-11 <https://www.ncbi.nlm.nih.gov/pubmed/29340648>
2. Yu, S, Frueh, BE, Steinmair, D, Ebnetter, A, Wolf, S, Zinkernagel, MS, Munk, MR. **Cataract Significantly Influences Quantitative Measurements on Swept-Source Optical Coherence Tomography Angiography Imaging.** *PLoS One.* 2018 Oct 2;13(10):e0204501 <https://www.ncbi.nlm.nih.gov/pubmed/30278057>
3. Tan, B, Chua, J, Barathi, VA, Baskaran, M, Chan, A, Lin, E, Ang, M, Klose, G, Schmetterer, L. **Quantitative Analysis of Choriocapillaris in Non-Human Primates Using Swept-Source Optical Coherence Tomography Angiography (SS-OCTA).** *Biomed Opt Express.* 2018 Dec 22;10(1):356-71 <https://www.ncbi.nlm.nih.gov/pubmed/30775105>
4. Rabiolo, A, Gelormini, F, Sacconi, R, Cicinelli, MV, Triolo, G, Bettin, P, Nouri-Mahdavi, K, Bandello, F, Querques, G. **Comparison of Methods to Quantify Macular and Peripapillary Vessel Density in Optical Coherence Tomography Angiography.** *PLoS One.* 2018 Oct 18;13(10):e0205773 <https://www.ncbi.nlm.nih.gov/pubmed/30335815>
5. Rabiolo, A, Gelormini, F, Marchese, A, Cicinelli, MV, Triolo, G, Sacconi, R, Querques, L, Bandello, F, Querques, G. **Macular Perfusion Parameters in Different Angiocube Sizes: Does the Size Matter in Quantitative Optical Coherence Tomography Angiography?** *Invest Ophthalmol Vis Sci.* 2018 Jan 1;59(1):231-37 <https://www.ncbi.nlm.nih.gov/pubmed/29340651>
6. Dolz-Marco, R, Glover, JP, Gal-Or, O, Litts, KM, Messinger, JD, Zhang, Y, Cozzi, M, Pellegrini, M, Freund, KB, Staurengi, G, Curcio, CA. **Choroidal and Sub-Retinal Pigment Epithelium Caverns: Multimodal Imaging and Correspondence with Friedman Lipid Globules.** *Ophthalmology.* 2018 Aug;125(8):1287-1301 <https://www.ncbi.nlm.nih.gov/pubmed/29625839>
7. Chu, Z, Zhou, H, Cheng, Y, Zhang, Q, Wang, RK. **Improving Visualization and Quantitative Assessment of Choriocapillaris with Swept-Source OCTA through Registration and Averaging Applicable to Clinical Systems.** *Sci Rep.* 2018 Nov 14;8(1) <https://www.nature.com/articles/s41598-018-34826-5>
8. Chu, Z, Zhang, Q, Zhou, H, Shi, Y, Zheng, F, Gregori, G, Rosenfeld, PJ, Wang, RK. **Quantifying Choriocapillaris Flow Deficits Using Global and Localized Thresholding Methods: A Correlation Study.** *Quant Imaging Med Surg.* 2018 Dec;8(11):1102 <https://www.ncbi.nlm.nih.gov/pubmed/30701164>
9. Zhang, Q, Chen, CL, Chu, Z, Zheng, F, Miller, A, Roisman, L, Rafael de Oliveira Dias, J, Yehoshua, Z, Schaal, KB, Feuer, W, Gregori, G, Kubach, S, An, L, Stetson, PF, Durbin, MK, Rosenfeld, PJ, Wang, RK. **Automated Quantitation of Choroidal Neovascularization: A Comparison Study between Spectral-Domain and Swept-Source OCT Angiograms.** *Invest Ophthalmol Vis Sci.* 2017 Mar 1;58(3):1506-13 <https://www.ncbi.nlm.nih.gov/pubmed/28273317>
10. Chu, Z, Lin, J, Gao, C, Xin, C, Zhang, Q, Chen, CL, Roisman, L, Gregori, G, Rosenfeld, PJ, Wang, RK. **Quantitative Assessment of the Retinal Microvasculature Using Optical Coherence Tomography Angiography.** *J Biomed Opt.* 2016 Jun 1;21(6):66008 <https://www.ncbi.nlm.nih.gov/pubmed/27286188>

Healthy Subjects

1. Zheng, F, Zhang, Q, Shi, Y, Russell, JF, Motulsky, EH, Banta, JT, Chu, Z, Zhou, H, Patel, NA, de Sisternes, L, Durbin, MK, Feuer, W, Gregori, G, Wang, R, Rosenfeld, PJ. **Age-Dependent Changes in the Macular Choriocapillaris of Normal Eyes Imaged with Swept-Source OCT Angiography.** *Am J Ophthalmol.* 2019 Apr;200:110-22 <https://www.ncbi.nlm.nih.gov/pubmed/30639367>
2. Zhou, H, Chu, Z, Zhang, Q, Dai, Y, Gregori, G, Rosenfeld, PJ, Wang, RK. **Attenuation Correction Assisted Automatic Segmentation for Assessing Choroidal Thickness and Vasculature with Swept-Source OCT.** *Biomed Opt Express.* 2018;9(12):6067-80 <https://www.osapublishing.org/boe/abstract.cfm?uri=boe-9-12-6067>
3. Zhang, Q, Shi, Y, Zhou, H, Gregori, G, Chu, Z, Zheng, F, Motulsky, EH, de Sisternes, L, Durbin, M, Rosenfeld, PJ, Wang, RK. **Accurate Estimation of Choriocapillaris Flow Deficits Beyond Normal Intercapillary Spacing with Swept-Source Oct Angiography.** *Quant Imaging Med Surg.* 2018 Aug;8(7):658-66 <https://www.ncbi.nlm.nih.gov/pubmed/30211033>
4. Wang, F, Zhang, Q, Deegan, AJ, Chang, J, Wang, RK. **Comparing Imaging Capabilities of Spectral Domain and Swept-Source Optical Coherence Tomography Angiography in Healthy Subjects and Central Serous Retinopathy.** *Eye Vis (Lond).* 2018 Aug 8;5:19 <https://www.ncbi.nlm.nih.gov/pubmed/30094272>
5. Sugano, Y, Sekiryu, T, Furuta, M, Tomita, R, Shintake, H, Maehara, H, Ojima, A. **Morphometrical Evaluation of the Choriocapillaris Imaged by Swept-Source Optical Coherence Tomography Angiography.** *Clin Ophthalmol.* 2018 Nov 5;12:2267-76 <https://www.ncbi.nlm.nih.gov/pubmed/30464388>
6. Shoji, T, Yoshikawa, Y, Kanno, J, Ishii, H, Ibuki, H, Ozaki, K, Kimura, I, Shinoda, K. **Reproducibility of Macular Vessel Density Calculations Via Imaging with Two Different Swept-Source Optical Coherence Tomography Angiography Systems.** *Transl Vis Sci Technol.* 2018 Dec 21;7(6):31 <https://www.ncbi.nlm.nih.gov/pubmed/30619651>
7. Nassisi, M, Baghdasaryan, E, Tepelus, T, Asanad, S, Borrelli, E, Sadda, SR. **Topographic Distribution of Choriocapillaris Flow Deficits in Healthy Eyes.** *PLoS One.* 2018 Nov 15;13(11):e0207638 <https://www.ncbi.nlm.nih.gov/pubmed/30440050>
8. Maruko, I, Kawano, T, Arakawa, H, Hasegawa, T, Iida, T. **Visualizing Large Choroidal Blood Flow by Subtraction of the Choriocapillaris Projection Artifacts in Swept-Source Optical Coherence Tomography Angiography in Normal Eyes.** *Sci Rep.* 2018 Oct 24;8(1):15694 <https://www.ncbi.nlm.nih.gov/pubmed/30356090>
9. Corvi, F, Pellegrini, M, Erba, S, Cozzi, M, Staurenghi, G, Giani, A. **Reproducibility of Vessel Density, Fractal Dimension, and Foveal Avascular Zone Using 7 Different Optical Coherence Tomography Angiography Devices.** *Am J Ophthalmol.* 2018 Feb;186:25-31 <https://www.ncbi.nlm.nih.gov/pubmed/29169882>
10. Chu, Z, Zhou, H, Cheng, Y, Zhang, Q, Wang, RK. **Improving Visualization and Quantitative Assessment of Choriocapillaris with Swept-Source OCTA through Registration and Averaging Applicable to Clinical Systems.** *Sci Rep.* 2018 Nov 14;8(1) <https://www.nature.com/articles/s41598-018-34826-5>
11. Akagi, T, Uji, A, Huang, AS, Weinreb, RN, Yamada, T, Miyata, M, Kameda, T, Ikeda, HO, Tsujikawa, A. **Conjunctival and Intrasceral Vasculatures Assessed Using Anterior Segment Optical Coherence Tomography Angiography in Normal Eyes.** *Am J Ophthalmol.* 2018 Dec;196:1-9 <https://www.ncbi.nlm.nih.gov/pubmed/30099035>
12. Mehta, N, Zahid, S, Chiu, BQ, Bhardwa, S, Tsui, E, Young, E, Young, JA, Jung, JJ. **Refinement of Fractal Analysis Methodology of Swept-Source Optical Coherence Tomography Angiography Images of Normal Eyes.** *Invest Ophthalmol Vis Sci.* 2017 Jun;58(8):1675 <https://iovs.arvojournals.org/article.aspx?articleid=2639505&resultClick=1>
13. Straub, J, Leahy, C, Luu, JY. **Wide-Field Swept-Source OCT En-Face Image Montages in Healthy Eyes.** *Invest Ophthalmol Vis Sci.* 2016 Sep;57(12):441 <http://iovs.arvojournals.org/article.aspx?articleid=2557941&resultClick=1>

14. Luu, JY, Sha, P, Durbin, M. **Comparison of Spectral-Domain and Swept-Source Optical Coherence Tomography Choroidal Thickness Measurements in Normal Eyes.** *Invest Ophthalmol Vis Sci.* 2016 Sep;57(12):2178 <https://iovs.arvojournals.org/article.aspx?articleid=2560681&resultClick=1>
15. Gregori, G, Rosenfeld, PJ, Roisman, L, Schaal, KB. **Automated Retinal Segmentation for Widefield OCT, with Applications to Oct Angiography.** *Invest Ophthalmol Vis Sci.* 2016 Sep;57(12):446 <https://iovs.arvojournals.org/article.aspx?articleid=2559294&resultClick=1>
16. Coffey, VC. **Advanced OCT: Making Waves in the Market.** *Opt Photonics News.* 2016;27(9):26-33 <https://www.osapublishing.org/opn/abstract.cfm?uri=opn-27-9-26>
17. Yi, J, Matsunaga, D, Legarreta, JE, Legarreta, AD, Gregori, G, Durbin, M, Sharma, A, Rosenfeld, PJ, Puliafito, C, Kashani, AH. **OCT Angiography (OCTA) in Healthy Human Subjects.** *Invest Ophthalmol Vis Sci.* 2015 Jun;56(7):3318 <https://iovs.arvojournals.org/article.aspx?articleid=2333173&resultClick=1>
18. Kuehlewein, L, Tepelus, TC, An, L, Durbin, MK, Srinivas, S, Sadda, SR. **Noninvasive Visualization and Analysis of the Human Parafoveal Capillary Network Using Swept-Source OCT Optical Microangiography.** *Invest Ophthalmol Vis Sci.* 2015 Jun;56(6):3984-8 <https://www.ncbi.nlm.nih.gov/pubmed/26087363>
<https://iovs.arvojournals.org/article.aspx?articleid=2337491>
19. Huang, Y, Zhang, Q, Thorell, MR, An, L, Durbin, MK, Laron, M, Sharma, U, Gregori, G, Rosenfeld, PJ, Wang, RK. **Swept-Source OCT Angiography of the Retinal Vasculature Using Intensity Differentiation-Based Optical Microangiography Algorithms.** *Ophthalmic Surg Lasers Imaging Retina.* 2014 Sep-Oct;45(5):382-89 <https://www.ncbi.nlm.nih.gov/pmc/articles/PMC4286454/>
<https://www.ncbi.nlm.nih.gov/pmc/articles/PMC4286454/pdf/nihms648133.pdf>
20. Arya, M, Rebhun, CB, Alibhai, AY, Chen, X, Moreira-Neto, C, Baumal, CR, Reichel, E, Witkin, AJ, Duker, JS, Sadda, SR, Waheed, NK. **Parafoveal Retinal Vessel Density Assessment by Optical Coherence Tomography Angiography in Healthy Eyes.** *Ophthalmic Surg Lasers Imaging Retina.* 2018 Oct 15;49(10):S5-17 <https://www.ncbi.nlm.nih.gov/pubmed/30339262>

Swept-Source OCT & OCTA Technology

1. Lee, WD, Devarajan, K, Chua, J, Schmetterer, L, Mehta, JS, Ang, M. **Optical Coherence Tomography Angiography for the Anterior Segment.** *Eye Vis (Lond).* 2019 Feb 1;6(4) <https://eandv.biomedcentral.com/articles/10.1186/s40662-019-0129-2>
2. Tan, B, Wong, A, Bizheva, K. **Enhancement of Morphological and Vascular Features in OCT Images Using a Modified Bayesian Residual Transform.** *Biomed Opt Express.* 2018 Apr 27;9(5):2394-2406 <https://www.ncbi.nlm.nih.gov/pubmed/29760996>
3. Sacconi, R, De Vitis, LA, Carnevali, A, Albertini, G, Cavalleri, M, Querques, L, Querques, G, Bandello, F, Shields, CL, DiNicola, M, Shields, JA. **Diagnostic and Therapeutic Challenges.** *Retina.* 2018 May;38(5):1058-61 <https://www.ncbi.nlm.nih.gov/pubmed/28654456>
4. Sacconi, R, Borrelli, E, Corbelli, E, Capone, L, Rabiolo, A, Carnevali, A, Casaluci, M, Gelormini, F, Querques, L, Bandello, F, Querques, G. **Quantitative Changes in the Ageing Choriocapillaris as Measured by Swept-Source Optical Coherence Tomography Angiography.** *Br J Ophthalmol.* 2018 Oct 25. doi: 10.1136/bjophthalmol-2018-313004 [Epub ahead of print] <https://www.ncbi.nlm.nih.gov/pubmed/30361273>

5. Li, Y, Xia, X, Paulus, Y. **Advances in Retinal Optical Imaging.** *Photonics*. 2018 Apr 27;5(2) <https://www.mdpi.com/2304-6732/5/2/9>
6. Jung, JJ, Chen, MH, Frambach, CR, Rofagha, S, Lee, SS. **Spectral Domain Versus Swept-Source Optical Coherence Tomography Angiography of the Retinal Capillary Plexuses in Sickle Cell Maculopathy.** *Retin Cases Brief Rep*. 2018 Spring;12(2):87-92 <https://www.ncbi.nlm.nih.gov/pubmed/27749746>
7. Balaratnasingam, C, An, D, Sakurada, Y, Lee, CS, Lee, AY, McAllister, IL, Freund, KB, Sarunic, M, Yu, DY. **Comparisons between Histology and Optical Coherence Tomography Angiography of the Periarterial Capillary-Free Zone.** *Am J Ophthalmol*. 2018 May;189:55-64 <https://www.ncbi.nlm.nih.gov/pubmed/29470970>
8. Zhang, Q, Chen, C-L, Chu, Z, Wang, RK. **Wide Field OCT Angiography by Using Swept-Source OCT in Living Human Eye.** *Ophthalmic Technologies XXVII*. 2017 Feb 8;10045:100450V doi: 10.1117/12.2251029 https://spie.org/Publications/Proceedings/Paper/10.1117/12.2251029?origin_id=x4318
<https://www.spiedigitallibrary.org/conference-proceedings-of-spie/10045/1/Wide-field-OCT-angiography-by-using-swept-source-OCT-in/10.1117/12.2251029.short?SSO=1>
9. Tumlinson, AR, Rahman, F, Magazzeni, S, Rochendorfer, P, Shemonski, N. **The Advanced Retina Imaging Network Hub Online Tools for Oct Innovation.** *Invest Ophthalmol Vis Sci*. 2017 Jun;58(8):1864 <https://iovs.arvojournals.org/article.aspx?articleid=2639646&resultClick=1>
10. Su, GL, Baughman, DM, Zhang, Q, Rezaei, K, Lee, AY, Lee, CS. **Comparison of Retina Specialist Preferences Regarding Spectral-Domain and Swept-Source Optical Coherence Tomography Angiography.** *Clin Ophthalmol*. May 15;11:889-95 <https://www.ncbi.nlm.nih.gov/pubmed/28553068>
<https://www.dovepress.com/getfile.php?fileID=36484>
11. Novais, EA, Baupal, C. **The Clinical Utility of OCT Angiography.** Review of Ophthalmology website <https://www.reviewofophthalmology.com/article/the-clinical-utility-of-oct-angiography>. January 10, 2017
12. Lang, GE, Enders, C, Loidl, M, Lang, GK, Werner, JU. **[Accurate OCT-Angiography Interpretation – Detection and Exclusion of Artifacts].** [Article in German] *Klin Monbl Augenheilkd*. 2017 Sep;234(9):1109-118 <https://www.ncbi.nlm.nih.gov/pubmed/28628928>
13. Kashani, AH, Chen, CL, Gahm, JK, Zheng, F, Richter, GM, Rosenfeld, PJ, Shi, Y, Wang, RK. **Optical Coherence Tomography Angiography: A Comprehensive Review of Current Methods and Clinical Applications.** *Prog Retin Eye Res*. 2017 Sep;60:66-100 <https://www.ncbi.nlm.nih.gov/pubmed/28760677>
14. Fathipour, V, Schmoll, T, Bonakdar, A, Wheaton, S, Mohseni, H. **Demonstration of Shot-Noise-Limited Swept-Source OCT without Balanced Detection.** *Sci Rep*. 2017 Apr 26;7(1):1183 <https://www.ncbi.nlm.nih.gov/pubmed/28446793>
https://www.ncbi.nlm.nih.gov/pmc/articles/PMC5430670/pdf/41598_2017_Article_1339.pdf
15. Cole, ED, Duker, JS. **Oct Technology: Will We Be “Swept” Away?** Review of Ophthalmology website. <https://www.reviewofophthalmology.com/article/oct-technology-will-we-be-swept-away>. April 7, 2017
16. Bagherinia, H, Knighton, RW, De Sisternes, L, Chen, MH, Durbin, M. **A Fast Method to Reduce Decorrelation Tail Artifacts in Oct Angiography.** *Invest Ophthalmol Vis Sci*. 2017 Jun;58(8):643 <https://iovs.arvojournals.org/article.aspx?articleid=2637956&resultClick=1>
17. Wang, RK, Zhang, A, Choi, WJ, Zhang, Q, Chen, CL, Miller, A, Gregori, G, Rosenfeld, PJ. **Wide-Field Optical Coherence Tomography Angiography Enabled by Two Repeated Measurements of B-Scans.** *Opt Lett*. 2016 May15;41(10):2330-3 <https://www.ncbi.nlm.nih.gov/pubmed/27176995>
18. Shahidzadeh, A, Kim, AY, Aziz, HA, Durbin, MK, Puliafito, C, Kashani, AH. **Widefield Swept-Source Optical Coherence Tomography Angiography.** *Invest Ophthalmol Vis Sci*. 2016 Sep;57(12):445 <https://iovs.arvojournals.org/article.aspx?articleid=2558091&resultClick=1>

19. Lavinsky, F, Lavinsky, D. **Novel Perspectives on Swept-Source Optical Coherence Tomography.** *Int J Retina Vitreous.* 2016 Nov 1;2(1):25 <https://www.ncbi.nlm.nih.gov/pubmed/27847643>
https://www.ncbi.nlm.nih.gov/pmc/articles/PMC5088466/pdf/40942_2016_Article_50.pdf
20. Kubach, S, Luu, JY, Lee, S, Jung, JJ, Rosenfeld, PJ, Gregori, G. **Importance of Sampling Density in the Analysis of Optical Coherence Tomography Angiography.** *Invest Ophthalmol Vis Sci.* 2016 Sep;57(12):4613 <https://iovs.arvojournals.org/article.aspx?articleid=2557949&resultClick=1>
21. Gregori, G, Rosenfeld, PJ, Roisman, L, Schaal, KB. **Automated Retinal Segmentation for Widefield OCT, with Applications to OCT Angiography.** *Invest Ophthalmol Vis Sci.* 2016 Sep;57(12):446
<https://iovs.arvojournals.org/article.aspx?articleid=2559294&resultClick=1>
22. Coffey, VC. **Advanced OCT: Making Waves in the Market.** . *Opt Photonics News.* 2016;27(9):26-33
<https://www.osapublishing.org/opn/abstract.cfm?uri=opn-27-9-26>
23. Huang, Y, Zhang, Q, Thorell, MR, An, L, Durbin, MK, Laron, M, Sharma, U, Gregori, G, Rosenfeld, PJ, Wang, RK. **Swept-Source OCT Angiography of the Retinal Vasculature Using Intensity Differentiation-Based Optical Microangiography Algorithms.** *Ophthalmic Surg Lasers Imaging Retina.* 2014 Sep-Oct;45(5):382-89 <https://www.ncbi.nlm.nih.gov/pmc/articles/PMC4286454/>
<https://www.ncbi.nlm.nih.gov/pmc/articles/PMC4286454/pdf/nihms648133.pdf>

EN_31_200_01581 Printed in the United States. CZ-IV/2019 International edition: Only for sale in selected countries.
 The contents of the compendium may differ from the current status of approval of the product or service offering in your country. Please contact our regional representatives for more information. Subject to changes in design and scope of delivery and as a result of ongoing technical development. PLEX Elite is either a trademark or registered trademark of Carl Zeiss Meditec AG or other companies of the ZEISS Group in Germany and/or other countries.
 © Carl Zeiss Meditec, Inc. 2019. All rights reserved.




Carl Zeiss Meditec, Inc.
 5160 Hacienda Drive
 Dublin, CA 94568
 USA
www.zeiss.com/swept-source
www.zeiss.com/med/contacts


Carl Zeiss Meditec AG
 Goeschwitzer Str. 51-52
 07745 Jena
 Germany
www.zeiss.com/swept-source
www.zeiss.com/med/contacts